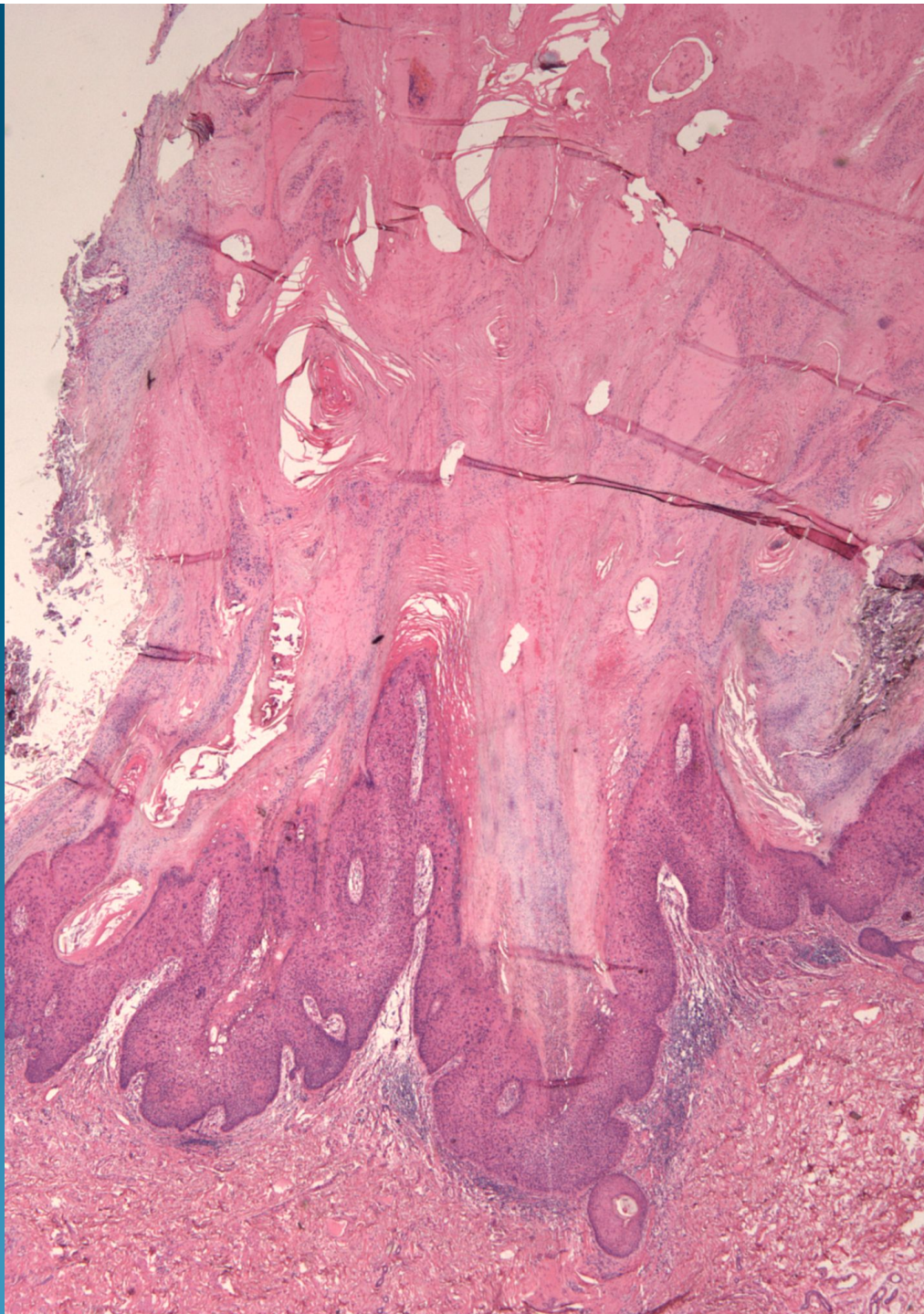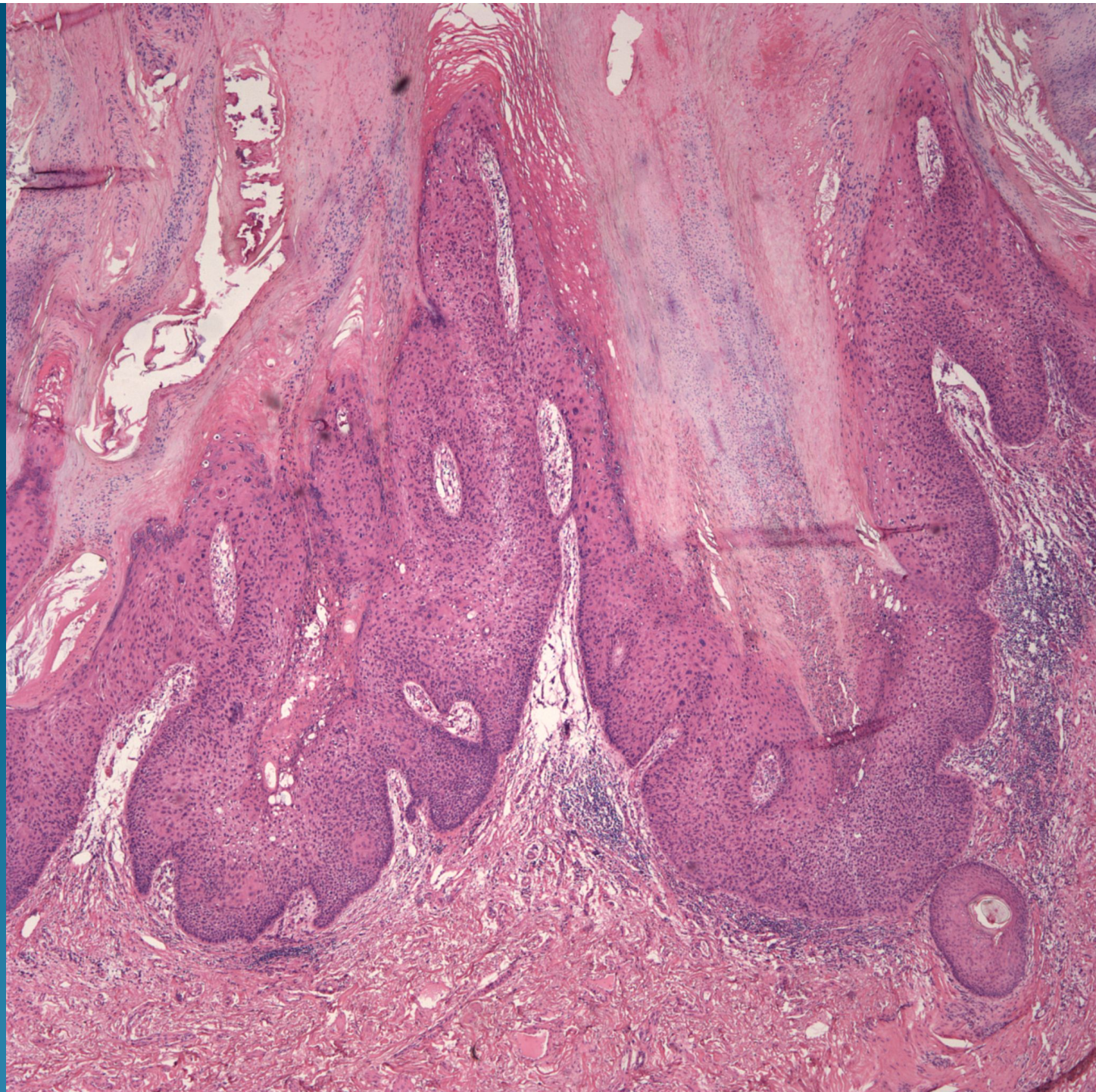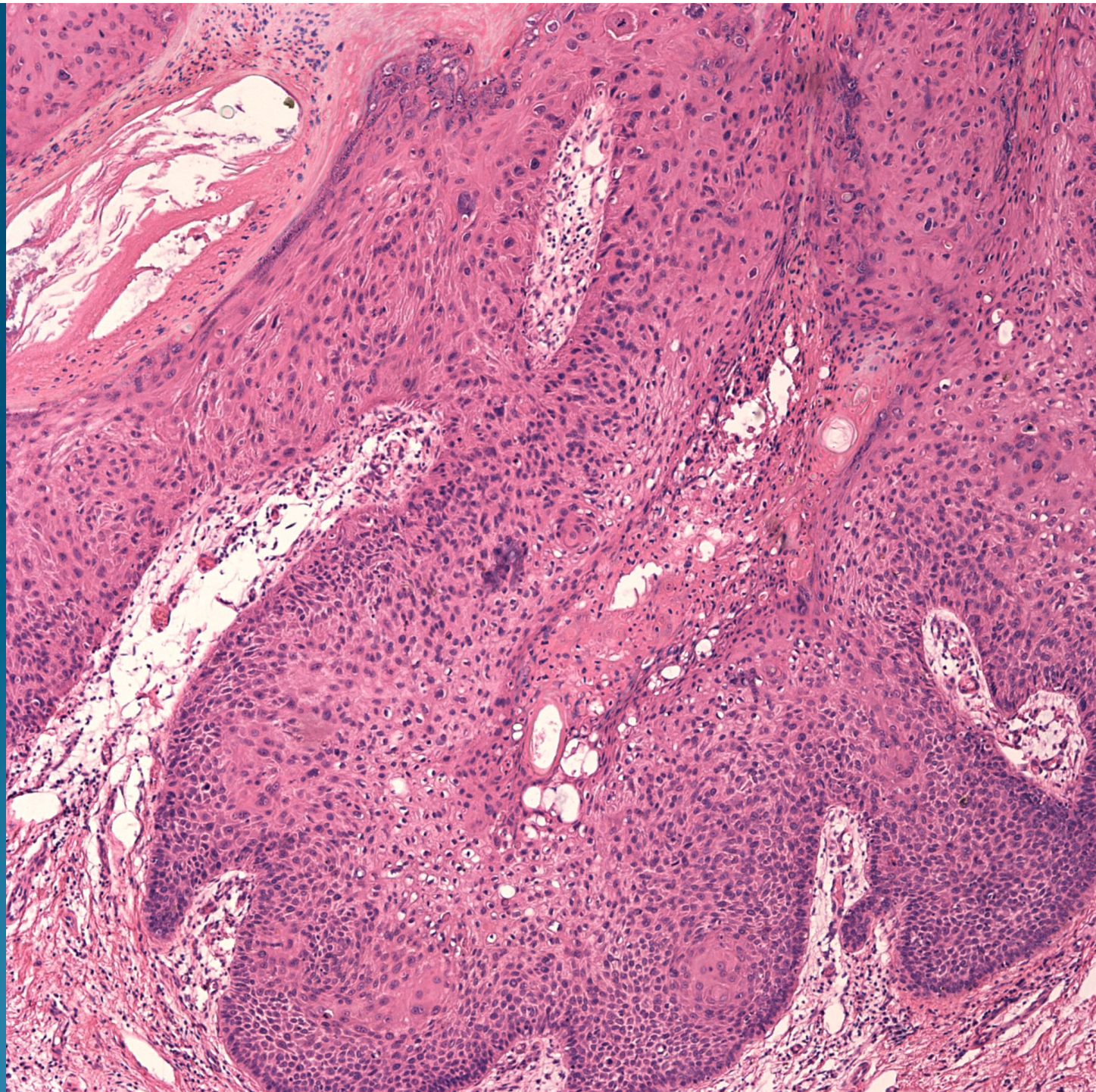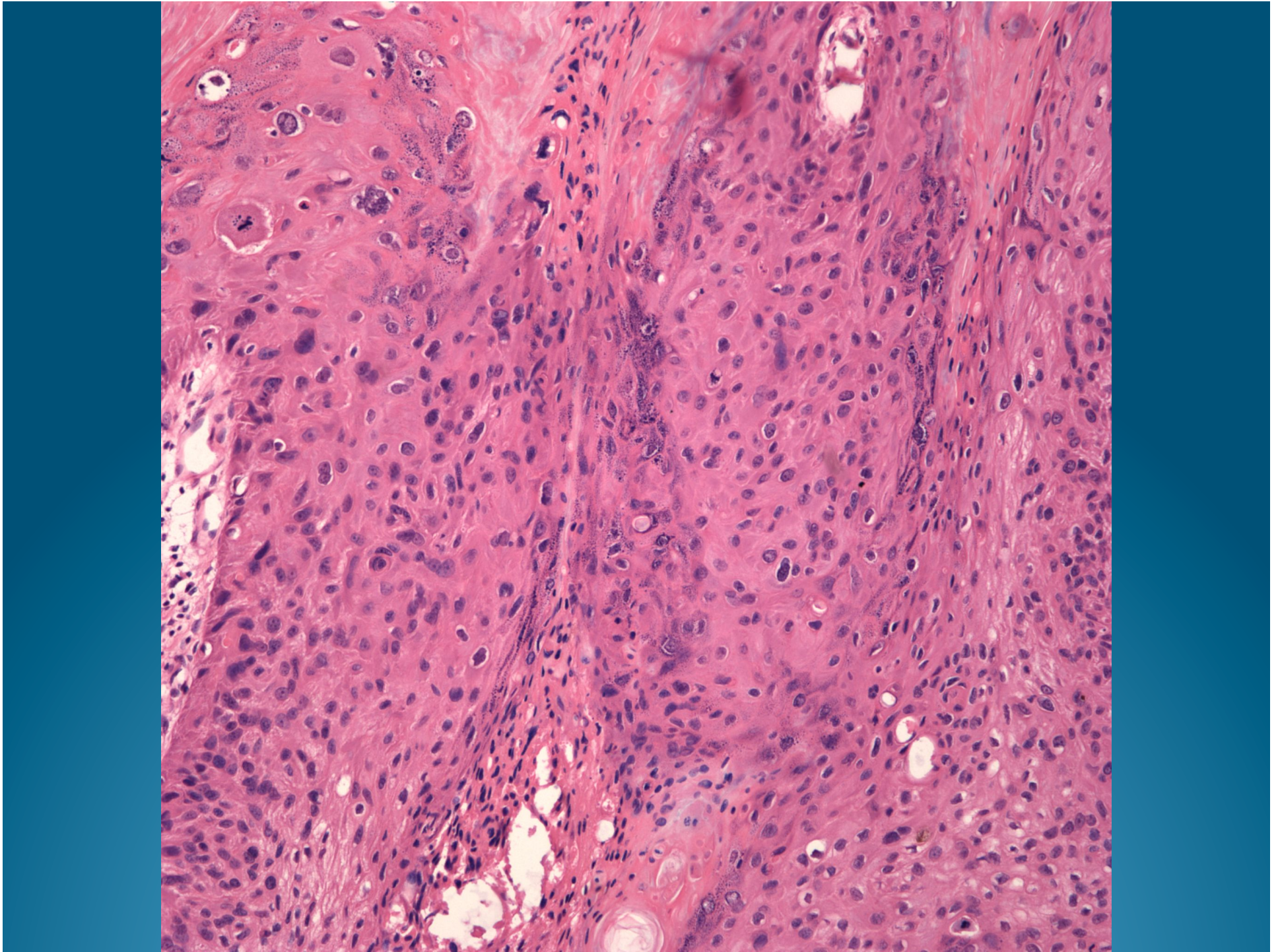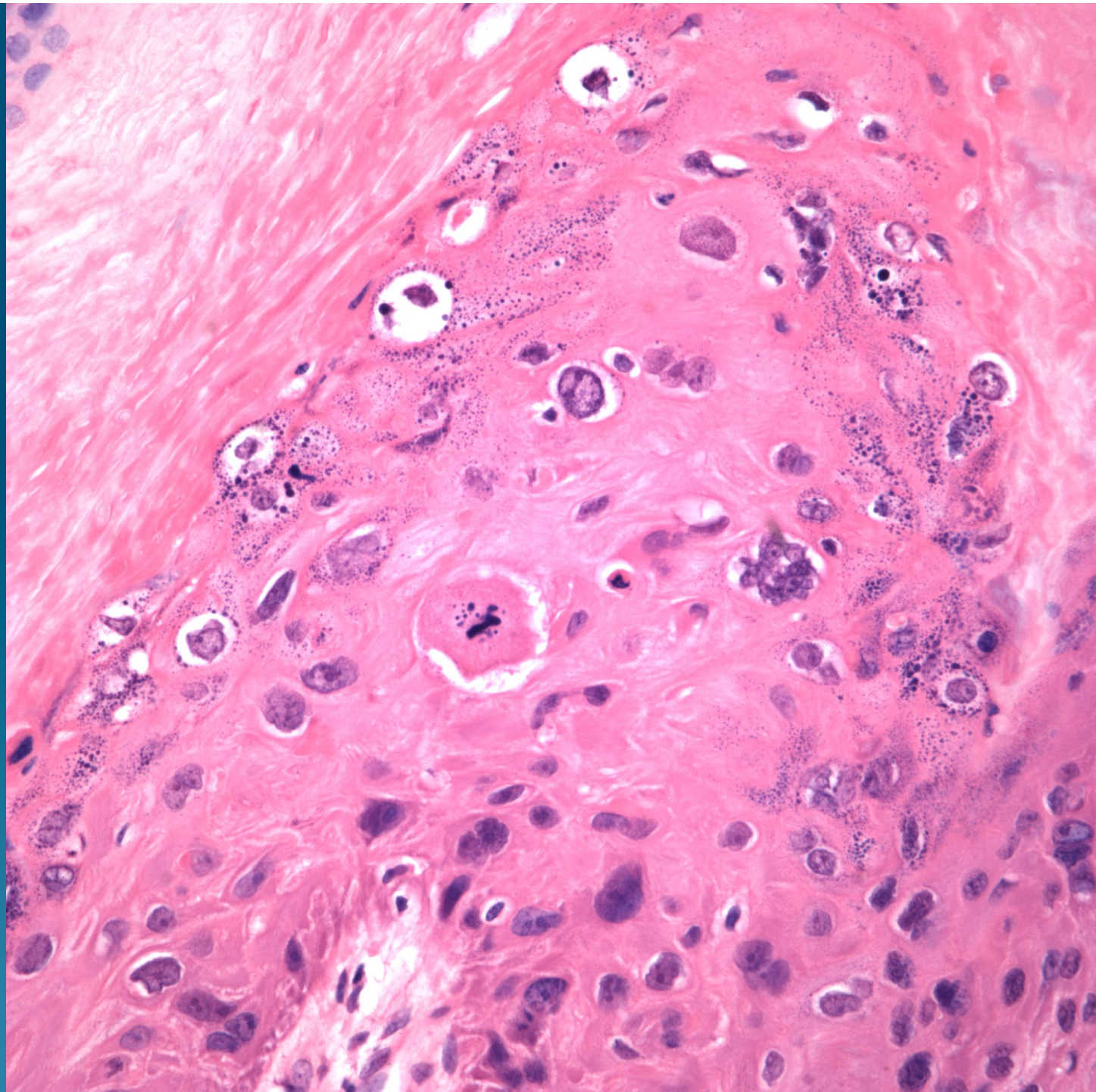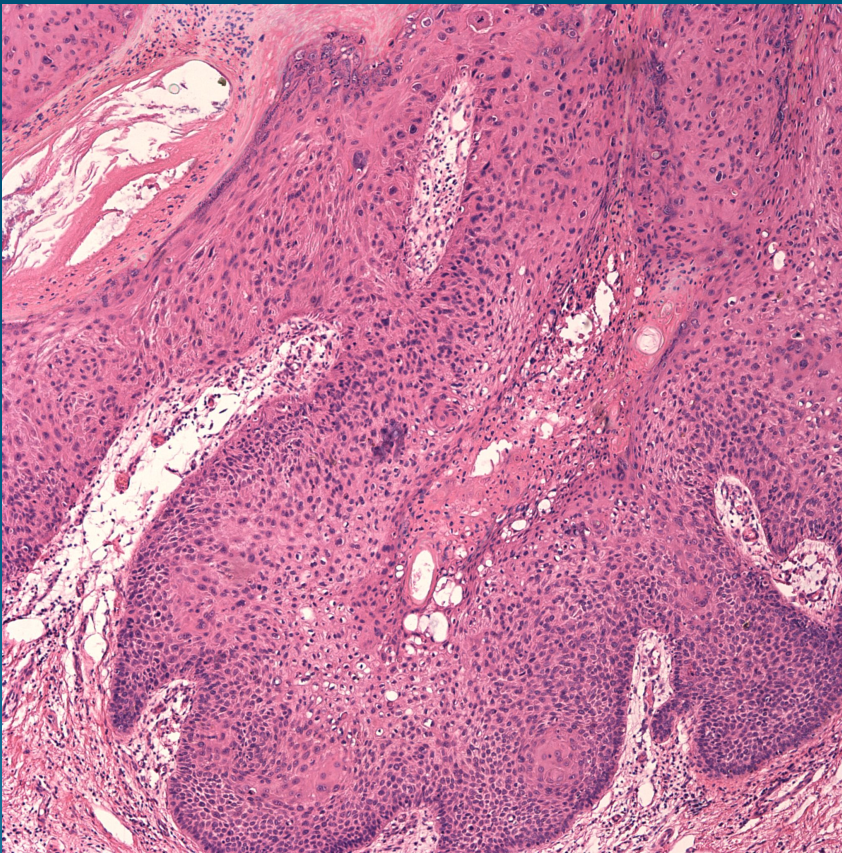


What is the best diagnosis?

- A. Verruca vulgaris
- B. Squamous cell carcinoma
- C. Basaloid squamous cell carcinoma
- D. Darier's disease
- E. Hypertrophic discoid lupus erythematosus

Penile Intraepithelial Neoplasia (PeIN) , Differentiated Type (Squamous Cell Carcinoma of Penis)

Pearls



- New diagnostic classification for squamous epithelial tumors (previously included erythroplasia of Queyrat)
- Full thickness replacement of squamous mucosa, akin to Bowen's disease
- If well differentiated keratinocytes, designate differentiated type. Basaloid or crowded cells have designated undifferentiated type